

**Case Report**

# Congenital Cystic Adenomatoid Malformation Type III Associated With Congenital Anomalies

Figen AKSOY, Rana RAMAZANOĞLU, Cihat ŞEN

*Department of Pathology, Gynecology Obstetrics Istanbul University Cerrahpaşa Faculty of Medicine-ISTANBUL***SUMMARY****CONGENITAL CYSTIC ADENOMATOID MALFORMATION TYPE III ASSOCIATED WITH CONGENITAL ANOMALIES****Background:** We present a case of congenital cystic adenomatoid malformation of the lung, type III, associated with congenital anomalies.**Observation:** Still born male fetus, whose karyotype found to be 46XY, was delivered to a 22 year old white female at 19th weeks of gestation. The parents of the baby were first degree relatives. During the follow-up of the pregnant a fetus with lomber bifid spine and ascites was observed. Clinical prediagnosis was cystic fibrosis. Upon examination of the internal organs, both of the lungs were found to be firm, bulky and had depressions of the ribs on their surfaces due to thoracic cage pressure. Cross sections showed a few scattered cysts 0.1-0.2 mm in diameter. Microscopic examination revealed alveolus-like structures lined by low cuboidal epithelium separated by loose mesenchymal interstitial tissue and some bronchiole-like structures spread in between. Additionally, cartilage and mucogenic cells, as well as elastic tissue and smooth or striated muscle fibers were not detected around these structures.**Conclusion:** With all these data in hand, our case is an example of Congenital Cystic Adenomatoid Malformation of the Lung, Stocker type III.**Key Words:** Congenital cystic adenomatoid malformation (CCAM), Congenital pulmonary airway malformation (CPAM)**ÖZET****KONJENİTAL ANOMALİLERİN EŞLİK ETTİĞİ BİR KONJENİTAL KİSTİK ADENOMATÖZ MALFORMASYON TİP III OLGUSU****Amaç:** Konjenital anomalilerin eşlik ettiği akciğere ait konjenital kistik adenomatöz malformasyon tip III olgusu sunuldu.**Olgu:** Karyotipi 46 XY olan ölü erkek bebek, gebeliğin 19. haftasındaki düşüğü takiben incelendi. Anne 22 yaşında olup eşi ile birinci dereceden akraba idi. Takipler sırasında fetusta asit ve spina bifida saptanmış ve kistik fibrozdan şüphelenildi. Otopside her iki akciğer sert ve büyük olup torasik basınca bağlı olarak kaburgaların izlerini taşımaktaydı. Kesitlerde birbirinden ayrı duran 0.1-0.2 mm çapında kistler mevcuttu. Mikroskopik incelemede, içinde bronşiole benzer yapılar bulunan gevşek bir mezankimal interstisyum ile birbirlerinden ayrılan, alçak kübik epitel ile döşeli alveol benzeri yapılar saptandı. Ayrıca bu yapıların çevresinde ne kıkırdak doku ve mukojen hücreler, ne de elastik doku ile düz veya çizgili kasa ait yapılara rastlandı.**Sonuç:** Bu bulgularla olguya akciğerin konjenital kistik adenomatoid malformasyonu, Stocker tip III tanısı koyuldu.**Anahtar Kelimeler:** Konjenital kistik adenomatoid malformasyonu, Konjenital pulmoner traktus malformasyonu

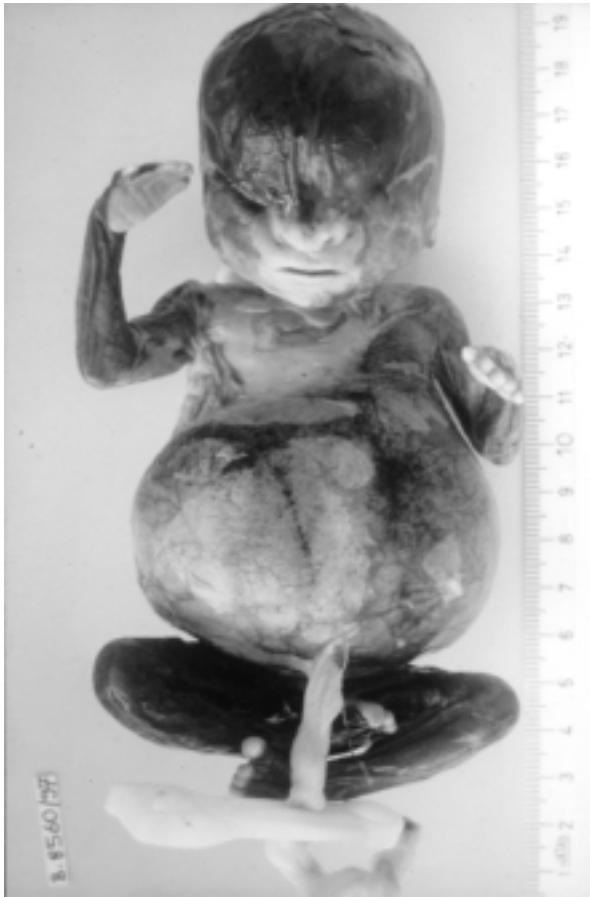**C**ongenital cystic adenomatoid malformation of the lung (CCAM) is a rare disorder mostly seen in newborn and stillborn infants (1). It is a developmental malformation of the lungs in which

there is a defect in formation of terminal and respiratory bronchioles and alveolar ducts (2).

Our case is a bilateral CCAM, type III associated with congenital anomalies. Because of the rarity of bilaterality in CCAM cases and association of congenital anomalies in CCAM type III, together with this case being the only one amongst our autopsies; we have found it worthwhile to report.

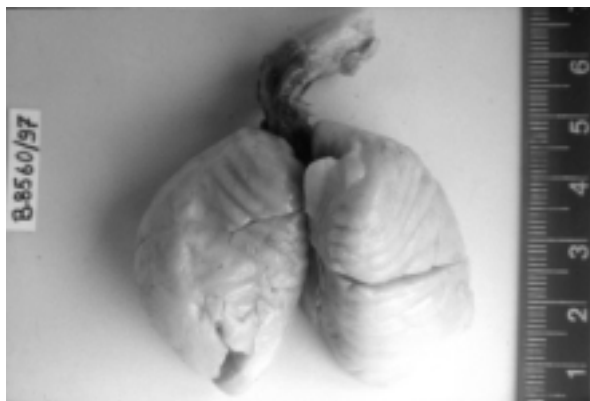**Yazışma Adresi:** Figen Aksoy

Istanbul Üniversitesi, Cerrahpaşa Tıp Fakültesi Patoloji Anabilim Dalı, Cerrahpaşa-İstanbul



**Figure 1.** Gross view of the fetus: stillborn male fetus at 19 week of gestation.

External abnormalities: Slightly large head, low set ears, fusion of the eyelids with globes properly placed, wide and depressed nasal root, chin smaller than normal, syndactyly, distended abdomen due to fetal ascites, lomber spina bifida, imperforated anus and maceration observed.



**Figure 2.** Grossly both of the lungs are firm and bulky, showing depressions on the surface due to thoracic cage pressure. A few scattered small cysts 0,1-0.2 mm in diameter seen both on the surface and in the cross section of the lungs.

## CASE

Our case is a stillborn male fetus weighing 250 gr, at 19th week of gestation, delivered to a 22-year old white female prima gravid. Mother, married her 1st degree relative (her uncle's son), smoked 5 cigarettes a day. During her follow-up in a non-university hospital, two anomalies, lomber spinabifida and fetal ascites were observed in USG and pancreatic cystic fibrosis was suspected. Upon tissue culture karyotype 46XY was determined.

## AUTOPSY FINDINGS

Gross autopsy examination revealed the following features: Macera male fetus with a slightly large head, low set ears with depression of the nasal root, fused eyelids with globes in proper position, syndactyly, chin smaller than normal, distended abdomen due to ascites, lomber bifid spine and imperforation of the anus (Figure 1).

In internal examination, grossly both of the lungs were firm, bulky and showed depressions on the surfaces due to thoracic cage pressure (Figure 2).

A few scattered small cysts 0.1-0.2 in mm diameter were observed both on the surface and the cross section of the lungs. Also there was a hematoma within the heart chambers, and ascites in the abdomen. No other abnormalities in internal or external organs were detected.

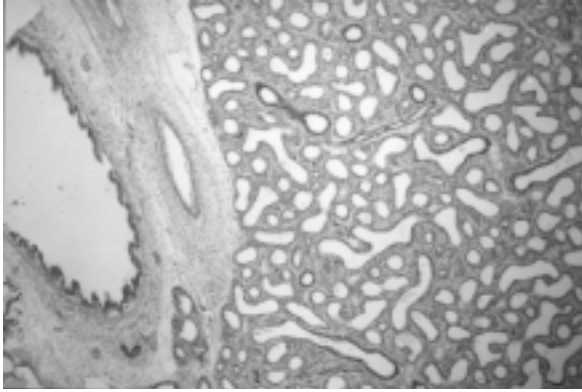
Upon microscopic examination the malformation was seen to consist of alveolus-like structures lined by low cuboidal epithelium separated by loose mesenchymal interstitial tissue and interspersed bronchiole-like structures (Figure 3A-3B).

Cartilage and mucogenic cells were not detected. No elastic tissue or smooth muscle were found around these structures. Also, no striated muscle were seen in the mesenchymal tissue. With these findings, our case demonstrates the pathological features of congenital cystic adenomatoid malformation of the lung, Stocker type III.

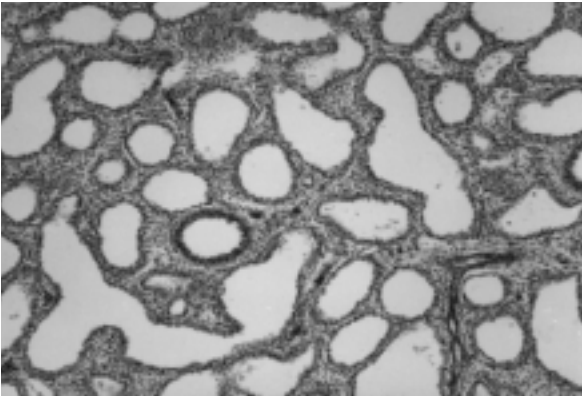
## DISCUSSION

Previously, the term "congenital cystic disease of the lung" was used for a wide variety of cystic pulmonary abnormalities upon detection of radiolucencies in chest roentgenograms without pathologic confirmation. A study by Koontz showed that some cases of cystic fibrosis, postinflammatory pneumatoceles and bronchiectasis as well as some sequestrations, hilar and bronchogenic cysts, and emphysematous lesions were reported as congenital cystic disease of the lung (5).

In 1949, separate entity, "congenital adenomatoid malformation of the lung" was designated by Chin and Tang (3). CCAM is a developmental mal-



**Figure 3A.** Fetal microscopic findings: Low-power view of the lung: A portion of the bronchus can be seen on the right and the multiple bronchiolar/alveolar duct like structures (resembling an immature lung) (HEX40).



**Figure 3B.** High power view of the lung: Microscopically, Bronchiolar/alveolus-like structures lined by low cuboidal epithelium surrounded by interstitial tissue mesenchymal in character (Type 3 CCAM) (HEX100).

formation of terminal and respiratory bronchioles and alveolar ducts (2). Althoughs, CCAM is mainly a disorder of the newborn and stillborn infants, there have been 2 adult cases of CCAM reported in the literature (1, 4).

The lesions seen in CCAM are most of the time unilateral (confined to one lobe/ segment/ whole lung); bilateral lesions were very rarely detected (1,5). Here, in our case we have encountered bilateral lesions in the lungs.

CCAM is usually accompanied with maternal polyhydramnions, hydrops fetalis and fetal ascites (1,5,6). Fetal ascites was present in the case we present.

On the other hand, congenital anomalies such as bilateral renal agenesis/dysgenesis, extralobar pulmonary sequestration, cardiovascular malformation, diaphragmatic hernia, jejunal atresia, pulmonary hypoplasia and skeletal malformations may be associated with this entity; most commonly in type II (3, 5, 6). Our case, CCAM type III, was

also associated with congenital anomalies.

Recently, a new attempt has been made by Dr. Thomas Stocker, MD, to rename this entity as "Congenital pulmonary airway malformation", for CCAM is a defect in differentiation of the tracheobronchial tree. According to Dr. Stocker, the classification of CCAM falls into 5 categories (7), which are:

**A. CCAM Type 0 (CPAM):** Acinar dysgenesis (agenesis)-Tracheobronchial origin.

**B. CCAM Type 1 (CPAM 1):** Large cyst type of bronchial/bronchiolar origin

**C. CCAM Type 2 (CPAM 2):** Intermediate cyst type of bronchiolar origin

**D. CCAM Type 3 (CPAM):** Small cyst type of bronchiolar/alveolar duct origin

CCAM Type 3 which almost exclusively occurs in males (as is the case we present), accounts for 8-10% of CCAM cases. In 79% of the cases it is associated with maternal polyhydramnions. This type of CCAM is the original congenital adenomatoid malformation of the lung described by Chin and Tang in 1949 (3).

Grossly, large bulky lesions involve the entire lobe or even an entire lung. In our case the lesions entirely involved both of the lungs.

Microscopically, lesions consist of randomly scattered bronchiolar/alveolar duct-like structures lined by low cuboidal epithelium, which are surrounded by alveoli lined by cuboidal epithelium (Figures 3A, 3B, 4A, 4B).

**E. Type 4 (CPAM 4):** Peripheral cyst type distal acinar origin.

In our 10-year series of autopsies we have had only a few CCAM case, with this case being the only one associated with congenital anomalies.

Briefly, we present a case of bilateral CCAM type 3 associated with congenital anomalies, diagnosed in the 2nd trimester as a still fetus.

## REFERENCES

1. Gilber E, Barness EG: Respiratory system. Potter's Pathology of the fetus and infants Ed. E. Gilbert, Ed, Bauness St Louis, Mosby, 1997; 741-6
2. Hutchin P, Friedman PJ, Saltzstein SL: Congenital cystic, adenomatoid malformation with anomalous blood supply. Thor Cardiovasc Surgj 1971; 62: 220-5
3. Bale PM: Congenital cystic malformation of lung. A form of congenital bronchiolar (adenomatoid) malformation. AJCP 1979; 71: 41-420
4. Askin FB: Respiratory tract disorders in the fetus and neonate. Textbook of fetal and perinatal pathology. Ed. J.S. Wigglessworth Ed. D.B. Singer 2. United states of America, Blackweel Science 1997; 567-71
5. Lauding BH, Dixon LQ: Congenital malformation and genetic disorders of the respiratory tract (larynx, trachea, bronchi and lungs). American Review of Respiratory Disease 1979; 120: 151-85
6. Stocker JT: The respiratory tract. Pediatric Pathology. Ed. JJ Stocker, Ed. LP Dehner. Philadelphia, J.B. Lippincott Company. 1991; 518-32
7. Stocker JT: XXII International Congress of the International Academy of Pathology and 13th world congress of Academic and Enviromental Pathology. October 18-23, 1998, Nice France. Symposium II 1998; 205-7